

COMPONENTS OF ENDODONTIC TREATMENT EFFECTIVENESS BASED ON LONG-TERM X-RAY CRITERIA

Nataliya Kobryn, Vitalii Hereliuk

Ivano-Frankivsk National Medical University

talyakobryn@gmail.com

Abstract. The objective of the research was to determine the effectiveness of obturation of the root canals and crown part of the teeth, and to identify the most important factors influencing its results, based on the X-ray examination.

Materials and methods: The study was conducted at the Dental Center (University Clinic, Ivano-Frankivsk National Medical University). Evaluation of 140 orthopantomograms, computed tomograms and digital intraoral images of spatient, aged 18-68 years with endodontically treated teeth, was made with the aim to determine the obturation state of root canals and the state of periodontal tissues. The radiological picture of 579 teeth and 1120 roots in particular was evaluated.

Results: the state of apical constriction, the state of obturation of root canals, sealing conditions of coronal part of the tooth, the state of periodontal tissues were analyzed, compared and discussed.

Conclusions: According to the results obtained in this study, the relationships between the presence of periapical changes and the state of apical constructions, obturation level of filling material in roots canals, coronal leakage, and periodontal tissue changes were found.

Keywords: *periapical changes, endodontic treatment, coronal leakage, X-ray examination*

Problem statement and analysis of the latest research

Nowadays, the need for endodontic treatment in Ukraine is quite high, but due to a number of factors, the effectiveness of this treatment is still insufficient with a high percentage of complications – from 30 up to 70% [1,2], meanwhile the success rate of endodontic treatment abroad is 85-91.45%, highlighted in foreign sources [3,4].

High-quality endodontic treatment directly depends on proper instrumental and medical processing of the root canal system in accordance with existing modern protocols, as well as the right choice of optimal filling material, taking into account peculiarities of clinical situation [5,6,7].

The success of this treatment also depends on the complexity of the morphological teeth structure, number of roots and roots canals, teeth position in the jaw. It is much more complicated to conduct high-quality endodontic treatment and obturate the multi-rooted teeth with curved root canals compared to single-rooted teeth with a straight canal [8,9,10]. Also, the effectiveness of endodontic treatment can be influenced by the following factors: the absence of periapical changes before the treatment, the level of root canal obturation within 2 mm to the radiographic apex, dense filling of root canal space without visible voids, and satisfactory crown restoration [11,12,13].

For understanding the reasons that could lead to unsuccessful endodontic treatment [14], it is necessary to take into account not only the absence or presence of radiological changes in the apical area, but also to consider additional criteria that can be obtained from

X-ray examination, namely apical constriction [15], root canal obturation, sealing condition of the orifice part of the canal [16,17,18], and the periodontal tissue conditions in the area of this tooth [19,20].

The objective of the research was to determine the effectiveness of obturation of the root canals and crown part of the teeth, and to identify the most important factors influencing its results, based on the X-ray examination.

Materials and methods

Determination of the obturation state of root canals and crown part of the teeth, and the state of periodontal tissues was performed on the basis of computed tomography [21,22,23] and digital orthopantomography, obtained using X-ray apparatus with a computed tomography function “Morita Veraviewepocs 3D” (Japan), and digital target radiography by using Heliodont Vario Sirona (intraoral universal sensor 2002), with a parallel stacking technique with dental positioners, followed by analysis in Sidexis 5.5, Sirona, conducted at the Dentistry Center of the University Clinic of Ivano-Frankivsk National Medical University.

140 orthopantomograms, computed tomograms and digital intraoral images of patients at the age of 18-68 were assessed. The endodontic treatment of root canals was the selection principle for further analysis. The radiological picture of 579 teeth and 1120 roots in particular was evaluated.

Computer programs based on Microsoft Excel 2019 were used for statistical processing of the research material.

Results

As a result of evaluation of radiological data, periapical changes were found around 518 (48.25%) roots and were absent around 602 (53.75%) roots. For more detailed study of endodontic treatment effectiveness, the following criteria were taken into account:

The state of apical constriction on radiological images: opened/closed.

State of canal obturation: overextension of filling material, material was traced at the level 1 mm to the apex, 2 mm to the apex, 3 mm to the apex, and more than 3 mm to the apex.

Sealing conditions of entrance part of the canal: tightness was preserved, tightness was disturbed.

The condition of periodontium around the tooth: the signs of periodontal pathology were present, signs of periodontal pathology were absent.

According to the data presented in Fig.1, apical constriction was destroyed (opened) in 358 roots (32%) and was preserved (closed) in 762 roots (68%).

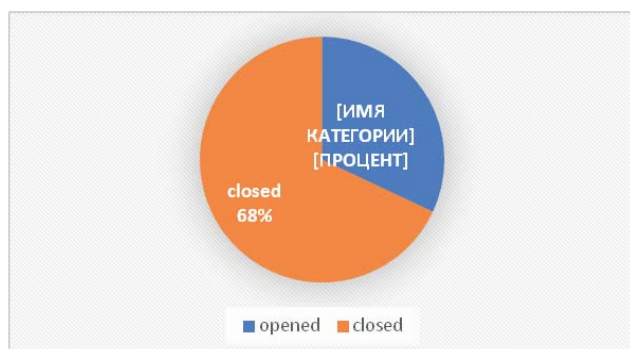


Figure 1. State of apical constriction

Radiological changes were found in the apical periodontium in (42.81±1.67) % of roots with closed apical constriction, while the changes were found in (59.07±3.19) % with opened apical constriction, which was significantly higher and indicated the negative impact of opened apical constriction on endodontic treatment. On the other hand, no radiological changes were observed in (57.19±1.67) % with closed constriction and only in (40.93±3.19) % with opened constriction which was a significantly better result and proved the benefits of closed apical constriction (Table1). Thus, changes in apical periodontium were more common in roots with

Table 1. State of apical periodontium around the teeth roots depending on the state of apical constriction

State of apical periodontium	State of apical constriction:			
	Opened, n=237		Closed, n=883	
	Amount	%	Amount	%
with radiological changes, n=518	140	59.07±3.19*!	378	42.81±1.67
without radiological changes, n=602	97	40.93±3.19	505	57.19±1.67

Note: *statically significant difference relative to indicators (p<0.05) without radiological changes

! statically significant difference relative to indicators (p<0.05) with opened constriction

opened apical constriction than with closed one, namely for 16% on average.

According to the analysis of the obturation level of root canals, the filling material was overextended in 50 roots (4.46%), sealed within 1 mm to the apex in 328 roots (29.29%), sealed within 2 mm to the apex in 295 roots (26.34%), sealed within 3 mm to the apex in 223 roots (19.91%), sealed above 3 mm to the apex in 224 roots (20%) (Fig. 2).

Table 2 showed the relationship between the obturation level of filling material in the root canal and the state of apical periodontium. Having analyzed the relationship between the obturation level of filling material and the state of apical periodontium, we found that statically significant changes occurred in the root canal with overextension of filling material, and where the obturation level was over 2 mm to the apex as well. Significantly rare periapical changes were noted when filling material was sealed within 1-2 mm to the apex: the changes were absent in (81.10±2.16)% of roots with the obturation level within 1mm to the apex and in (71.86±2.62)% of roots with obturation within 2 mm

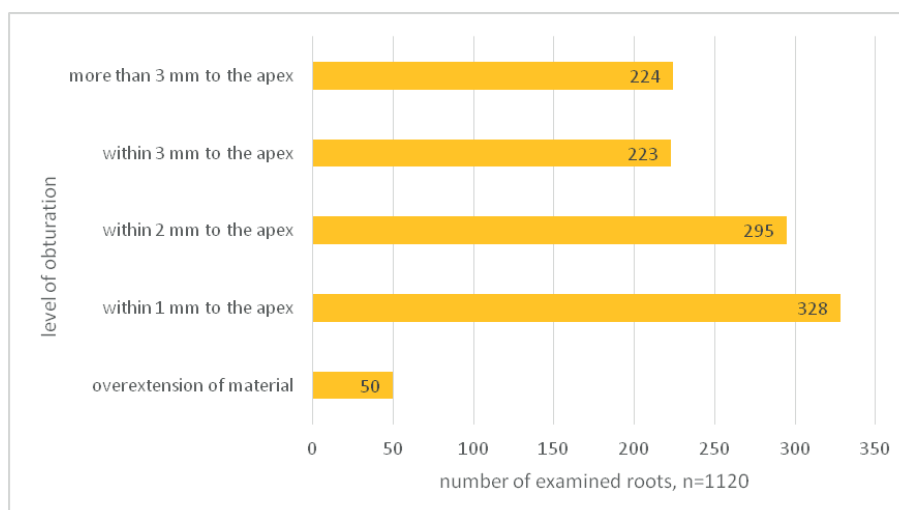


Figure 2. State of root canals obturation

Table 2. State of apical periodontium depending on the level of root canal obturation

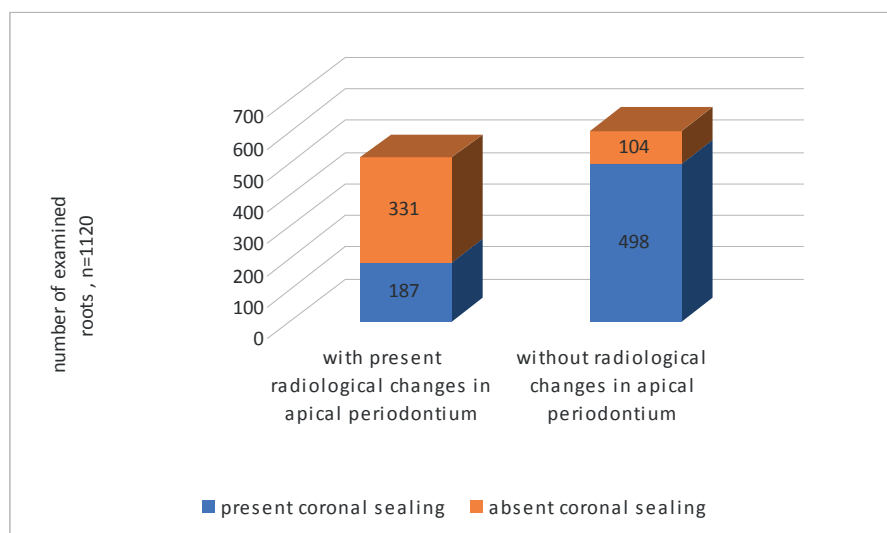
State of apical periodontium	State of obturation level									
	Overextension of material, n=50		Within 1 mm to the apex, n=328		Within 2 mm to the apex, n=295		Within 3 mm to the apex, n=223		Over 3 mm to the apex n=224	
with radiological changes, n=518	number	%	number	%	number	%	number	%	number	%
		47	94±3.36*	62	18.90±2.16*	83	28.14±2.62*	130	58.30±3.30*	196
without radiological changes, n=602	3	6±3.36	266	81.10±2.16	212	71.86±2.62	93	41.70±3.30	28	12.50±2.21

Note: *statically significant difference relative to indicators ($p < 0.05$) without radiological changes

to the apex.

While determining the condition of the apical periodontium, the preserved sealing of the entrance was noted in 685 roots constituting 61.16% of cases, and the coronal leakage was present in 435 roots amounting 38.84 % (Fig.3)

Periapical changes were less common in case of the absence of periodontal tissue changes, namely in (21.40±2.43) % of cases. In case of periodontal pathology observed on X-ray image, periapical changes occurred significantly more often, namely in (54.73±1.72) % of cases (Fig. 4).

**Figure 3. State of coronal sealing**

Structural changes in the apical periodontium were observed only in (27.30±1.7) % in case of reliable sealing in the coronal part. However, if the coronal leakage was present, periapical changes were detected in (76.90±2.05) %, that was significantly higher and indicated an essential impact of coronal leakage on the state of the apical periodontium (Table 3)

The condition of periodontal tissue was also taken into account during the analysis of X-ray images. According to the Table 4, radiological signs of periodontal pathology were present in 74.55% of cases (835 roots), while no signs of periodontal pathology were observed in about 25.45% of cases (285 roots).

absent in 602 roots, the obturation level was within 1 mm to the apex in (44.19±2.02) % of cases, and within 2 mm to the apex in (35.22±1.95) % of cases.

The coronal leakage was established to correlate with the higher rate of periapical changes.

The relation between the periapical changes and X-ray changes in periodontal tissue was proven.

Ethical standards (See Statement of Human and Animal Rights):

Conflict of interest: The authors report no conflicts of interest.

Conclusions

The relationship between the state of apical constriction and the periapical changes was found. Particularly, changes in the apical part of the roots were significantly more common when apical constriction was disturbed.

The obturation level of root canal affected the state of apical periodontium (periapical changes were found in 518 (46.25%) roots, filling material was traced over 3 mm to the apex in (37.84±2.13) % of cases and within 3 mm to the apex in (25.10±1.90) % of cases.

The periapical changes were

Table 3. State of apical periodontium depending on the state of coronal seal

State of apical periodontium:	State of coronal seal			
	Presence of coronal seal, n=685		Absence of coronal seal, n=435	
	Number of roots	%	Number of roots	%
with present radiological changes, n=518	187	27.30±1.7*	331	76.90±2.05*
without radiological changes, n=602	498	72.70±1.7	104	23.91±2.05

Note: *p<0.05 - statically significant difference relative to indicators without radiological changes

Table 4. State of apical periodontium depending on the state periodontal tissue

State of apical periodontium:	State of periodontal tissue			
	Present signs of periodontal tissue pathology, n=285		Absent signs of periodontal tissue pathology, n=835	
	number	%	number	%
with present radiological changes, n=518	61	21.40±2.43*	457	54.73±1.72*
without radiological changes, n=602	224	78.60±2.43	378	45.27±1.72

Note: *p<0.05 - statically significant difference relative to indicators without radiological changes

Financial Disclosure: This study was not financially supported by any funding.

References

1. Konova OV. Current status of endodontic treatment in the population of Ukraine. Current issues of modern medicine. 2015; 3(1): 296-305. Available from: <https://cyberleninka.ru/article/n/suchasniy-stan-endodontichnogo-likuvannya-pulpitu-u-naselennya-ukrayini/viewer>

2. Batig VM. The effectiveness of endodontic treatment in patients with generalized parodontitis with prevention of the sympatic vegetative nervous system. Modern Dentistry. 2020; 1:49-53. Available from: <https://doi.org/10.33295/1992-576X-2020-1-49>

3. Noboru Imura, Ericka T. Pinheiro, Brenda P.F.A. Gomes, Alexandre et al. The Outcome of Endodontic Treatment: A Retrospective Study of 2000 Cases Performed by a Specialist. Journal of Endodontics. 2007; 33(11): 1278-1282. Available from: <https://doi.org/10.1016/j.joen.2007.07.018>

4. Landys Borén et al. Long-term Survival of Endodontically Treated Teeth at a Public Dental Specialist Clinic. Journal of Endodontics. 2015; 42(2):176-181. Available from: <https://doi.org/10.1016/j.joen.2014.10.002>

5. Stoll R, Betke K, Staschniss V. The influence of different factors on the survival of root canal fillings: a 10-year retrospective study. J Endod. 2005; 31: 783-790. Available from: <https://doi.org/10.1097/01.don.0000158229.43298.a9>

6. European Society of Endodontology. Quality guidelines for endodontic

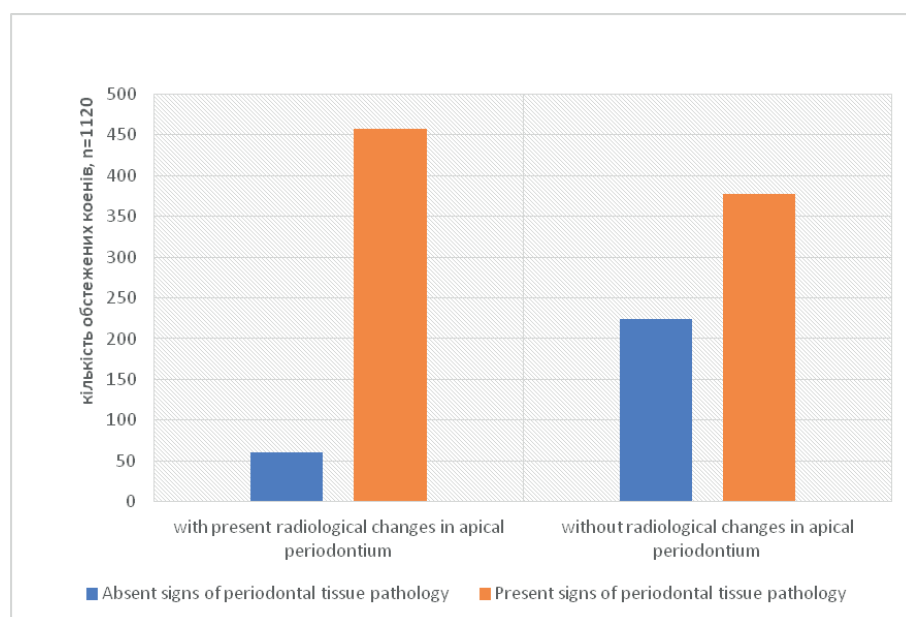


Figure 4. Relationship between changes in apical periodontium and in periodontal tissues

- treatment: consensus report of the European Society of Endodontology. *Int Endod J.* 2006 Dec; 39(12): 921-30. Available from: <https://doi.org/10.1111/j.1365-2591.2006.01180.x>
7. Chandra A. Discuss the factors that affect the outcome of endodontic treatment. *Australian Endodontic Journal*, 2009; 35: 98-107. Available from: <https://doi.org/10.1111/j.1747-4477.2009.00199.x>
8. Mothanna K, AlRahabi. Evaluation of complications of root canal treatment performed by undergraduate dental students, *Libyan Journal of Medicine*. 2017; 12: 1. Available from: <https://doi.org/10.1080/19932820.2017.1345582>
9. Carrotte PA. Clinical guide to endodontics – update part 1. *Br Dent J.* 2009; 206: 79-84. Available from: <https://doi.org/10.1038/sj.bdj.2009.6>
10. de Chevigny C, Dao T, Basrani BR et al. Treatment outcome in endodontics: the Toronto Study, phase 4 - initial treatment. *J Endod.* 2008; 34: 258-263 Available from: <https://doi.org/10.1016/j.joen.2007.10.017>
11. Hansrani V. Assessing root canal fillings on a radiograph - an overview. *Br Dent J.* 2015 Nov 27; 219(10): 481-3. Available from: <https://doi.org/10.1038/sj.bdj.2015.882>
12. Bernstein SD, Horowitz AJ, Man M, et al. Outcomes of endodontic therapy in general practice: a study by the Practitioners Engaged in Applied Research and Learning Network. *J Am Dent Assoc.* 2012; 143(5): 478-487. Available from: <https://doi.org/10.14219/jada.archive.2012.0208>
13. Leduc J, Fishelberg G. Endodontic obturation: a review. *General Dentistry.* 2003 May-Jun; 51(3): 232-233. Available from: <https://pubmed.ncbi.nlm.nih.gov/15055706/>
14. Lin LM, Skribner JE, Gaengler P. Factors associated with endodontic treatment failures. *J Endod.* 1992 Dec; 18(12): 625-7. Available from: [https://doi.org/10.1016/S0099-2399\(06\)81335-X](https://doi.org/10.1016/S0099-2399(06)81335-X)
15. Manak TN, Kliuyko KG. Study of the structure of the apical construction in different conditions of the canal-root system. *Endodontics Today.* 2018; 16(4): 35-39. Available from: <https://doi.org/10.25636/PMP.2.2018.4.8>
16. Amlani, Harsh & Hegde, Vivek. Microleakage: Apical Seal vs Coronal Seal. *World Journal of Dentistry.* 2013; 4: 113-116. Available from: <https://www.wjoud.com/doi/pdf/10.5005/jp-journals-10015-1215>
17. Pedro FM, Marques A, Pereira TM, Bandeca MC, Lima S, et al. Status of Endodontic Treatment and the Correlations to the Quality of Root Canal Filling and Coronal Restoration. *J. Contemp. Dent. Pract.* 2016; 17: 830–836. Available from: <https://www.thejcdp.com/doi/pdf/10.5005/jp-journals-10024-1939>
18. Mandke, Lalitagauri. Importance of coronal seal: Preventing coronal leakage in endodontics. *Journal of Restorative Dentistry.* 2016; 4(3): 71. Available from: 10.4103/2321-4619.188224.
19. Parolia A, Gait TC, Porto IC, Mala K. Endo-perio lesion: A dilemma from 19th until 21st century. *J Interdiscip Dentistry* 2013; 3: 2-11. Available from: <https://www.jidonline.com/text.asp?2013/3/1/2/120514> <https://doi.org/10.4103/2229-5194.120514>
20. Siew KL, Goh V, Goo CL, Leung, Corbet SF, Leung WK0. The Periodontal-Endodontic Relationship, What Do We Know? In: Manakil, J., editor. *Periodontology and Dental Implantology.* London: IntechOpen; 2018. Available from: <https://www.intechopen.com/chapters/62416> <https://doi.org/10.5772/INTECHOPEN.78664>
21. Patel, Shanon et al. The Impact of Different Diagnostic Imaging Modalities on the Evaluation of Root Canal Anatomy and Endodontic Residents' Stress Levels: A Clinical Study. *Journal of endodontics.* 2019; 45(4): 406-413. Available from: <https://doi.org/10.1016/j.joen.2018.12.001>
22. Patel S, Brown J, Semper M, Abella F, Mannocci F. European Society of Endodontology Position Statement: Use of Cone Beam Computed Tomography in Endodontics: European Society of Endodontology (ESE) Developed By. *Int. Endod. J.* 2019; 52: 1675–1678. Available from: <https://doi.org/10.1111/iej.13187>
23. Abella F, Patel S, Durán-Sindreu F, Mercadé M, Bueno R, Roig M. An evaluation of the periapical status of teeth with necrotic pulps using periapical radiography and cone-beam computed tomography. *International Endodontic Journal.* 2014; 47: 387-96. Available from: <https://doi.org/10.1111/iej.12159>

Received: 21.04.2022

Revised: 19.05.2022

Accepted: 20.05.2022