

Research Article

Use of Modern Methods of Diagnostic of Occlusal Disorders in Patients with Carious Disease

Khrystyna Oleksyn*, Mykola Rozhko

Abstract

Occlusal disorders are one of the key problems in dentistry. They are observed at many dental diseases, resulted in the emergence of pathological processes in chewing system. Tooth decay is one of the factors that leads to disorders of occlusion. The purpose of our research is the study of occlusal disorders in patients with carious disease using modern methods of diagnostics, namely, technology of laser fluorescence and computer analysis of occlusion. 110 students of first 3 years of study at Ivano-Frankivsk National Medical University at the age of 17-20 with carious lesions of first molars were examined for the diagnostic of relationship between occlusal contacts. They were the citizens of the regions with low level of fluoride. 20 students with carious lesion of the dentin were selected to determine the nature of occlusal disorders. Analysis of occlusion was performed with the help of computerized system T-Scan Novus. Results of the study indicate that carious process has direct impact on the occurrence of occlusal disorders.

Keywords

analysis of occlusion; occlusal disorders; carious lesions; early diagnostic of occlusal disorders

Ivano-Frankivsk National Medical University, Ivano-Frankivsk, Ukraine

*Corresponding author: hrystya15@yahoo.com

Problem statement and analysis of the latest research

Occlusion is the closure of dental arches or individual groups of teeth over a longer or shorter period of time in harmony with the temporomandibular joint (TMJ) and neuromuscular system (masticatory muscles). There is a static and dynamic occlusion. Static occlusion means certain spatial position of closure of dental arches. By Engle's definition, there are three classes of occlusion. This classification based on ration of molars. Dynamic occlusion is the interaction between the teeth in the movement of the lower jaw [11, 14, 15, 19].

Dental antagonist shows the functional complex, which includes a certain number of basic elements for stable closure of the jaws and performing of functional movements. Contacts of central relationships of the jaws are the guides to achieve the closing of the jaws. Their perfect location is on distolingual cusp ridge of mandibular first molars and mesiolingual cusp ridge of maxillary first molars, which leads to the possibility of movement of the lower jaw forward and up to achieve interarch (buccolingual) relationship. It was proved that starting point of contacts of central relationships in oral cavity could appear on different teeth. Such location of contacts of central relationships is considered as occlusal interferences [3, 4, 9, 11].

Occlusal interferences form a variety of displacement of the mandible when it closing under the influence of guide occlusal surfaces [4].

Alteration of occlusal relationships is observed in many

dental diseases. The consequence of that is the occurrence of pathological process in the chewing system [1, 3, 17].

Caries is one of the main reasons of occlusal disorders [11]. In economically developed counties it reaches 95-98% [12]. The carious process causes the changes in the location of occlusal contact points, which is the cause of atypical movements of the mandible. As a result, there is a tooth overload and formation of occlusal trauma [1, 11].

The molars play an important role in the development and function of the tooth-jaw system. The position of first molars determines the alignment of dentitions (Engle's classification) and height of central occlusion, their occlusal surfaces is the directional plane for the mandibular movements. The first molars are the functional center of chewing. Their occlusal surfaces are the most vulnerable places for caries process [7, 8, 17].

As a result of early caries lesion, these teeth change their anatomical shape and relationships with antagonists, which is the reason for the following occlusal disharmony [1, 7, 12, 19].

Their appearance leads to a violation of static and dynamic occlusion, which are causal and concomitant factors in the occurrence of changes in the temporomandibular joint. Tooth shape, contacts with adjacent teeth and antagonists are the main determinants of occlusal morphology, that provide the function of chewing, aesthetics, pronunciation and protection. The ignorance of these occlusal components leads to occlusal trauma (occlusal overloads) [1, 3, 6].

The purpose of the research.

The study of occlusal disorders in patient with carious

disease with the help of modern methods of diagnostic.

1. Materials and Methods

The clinical forms of caries of first molars were determined by 110 students, who live in the regions with low level of fluoride, with the use of diagnodent (Kavo), that functions with the help of technology of laser fluorescence, which allows to detect caries at different stages.

To determine occlusal disorders during carious disease and to study the correlative relationship between them we examined 20 students with the occlusal caries of the first molars with the help of computerized occlusion analysis system T-Scan Novus. It has allowed to visualize on the screen in 2D and 3D images of all the contacts that occur between the teeth of the upper and lower jaws, time and sequence of occurrence of contact, the location and the trajectory of the center of force (balance between right and left side).

2. Results and Discussion

The diagnostic principle of the diagnodent (Kavo) is based on laser fluorescence spectroscopy. Healthy and affected tissues of the tooth fluoresce differently when they reach the laser beam. So diagnodent (Kavo) signals carious process even if the teeth still seem healthy from the outside. That's why this method is much more informative than the traditional visual examination. It is also quite objective, since it does not require instrumental examination.

Data examination using laser fluorescence have shown that enamel caries was diagnosed in 8 students, deep enamel caries – 32 students, and dentin caries – 70 students (Fig. 1).

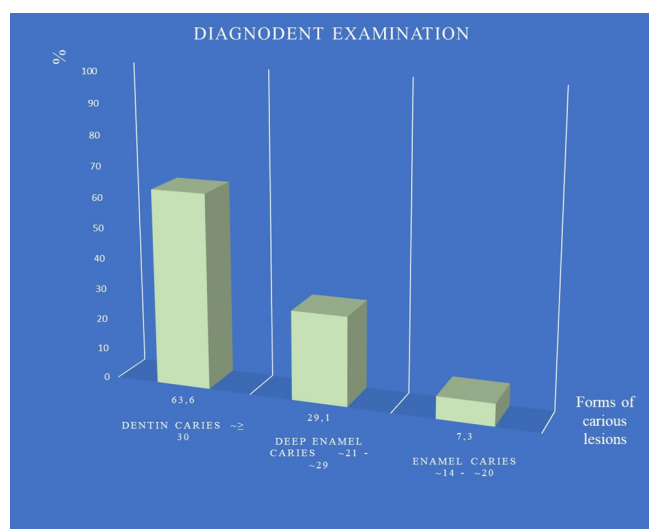


Figure 1. Clinical forms of carious lesions

Computer analysis of occlusion with the help of T-Scan Novus system was conducted by 20 students with carious lesion of first molars.

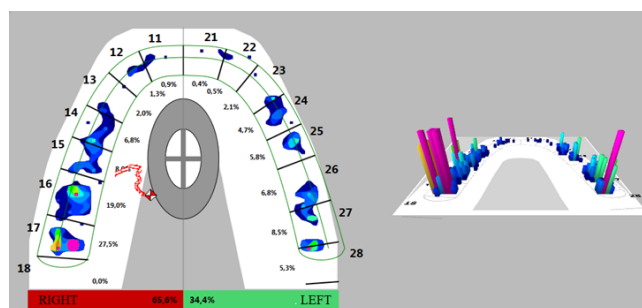


Figure 2.1. Dental caries of 16 tooth

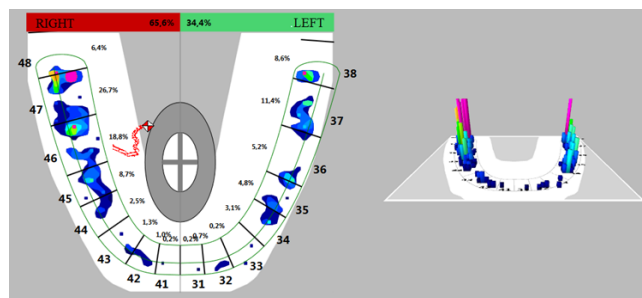


Figure 2.2. Dental caries of 16 tooth (antagonist)

Figure 2

Its results showed that presence of carious lesion of 16 (first molar) occurs chewing overload on the right side of the jaw, which increases to 65.6%. The occlusal interferences are missing on 16 tooth. Center of occlusion shifted on 17 tooth (second molar) and caused the increase of occlusal load on it up to 27.5%. Chewing load on the left side of the jaw decreased to 34.4%.

On 26 and 27 teeth the occlusal interferences are missing. Distribution of masticatory force is equal (Fig. 2.1). It is important to note, that we can observe the similar picture on opposite teeth. The force center is shifted on 47 tooth. There are occlusal interferences on it (Fig. 2.2).

The result of the examination of the patient with carious lesion of 36 tooth showed that chewing load on the right side of the jaw has been increased on 5.2%. Center of occlusion shifted on 37 tooth, as evidenced by an increase of occlusal load on it to 19.3%. Occlusal interferences are present on 37 tooth. 46 and 47 teeth distribute masticatory force (Fig. 3.1). Center of the force on upper jaw is located on 16 dental antagonist and reaches 19.9%, as opposed to 17 tooth on which the load is reduced to 6.6%. The similar situation is observed on the teeth of the opposite side of the mandible (Fig. 3.2).

It was determined insignificant fluctuation of chewing load between opposite sides of the jaw in one of the examined students. Also, the computerized analysis of occlusion showed that dental caries of 46 tooth leads to appearance of occlusal overload on 47 tooth, that increases to 26.6% with the next occurrence of occlusal interferences (Fig. 4.1). It is important

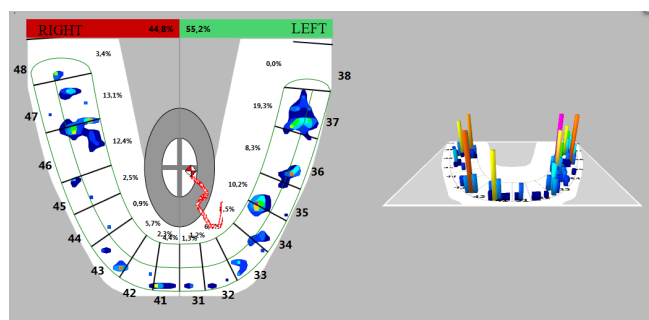


Figure 3.1. Dental caries of 36 tooth

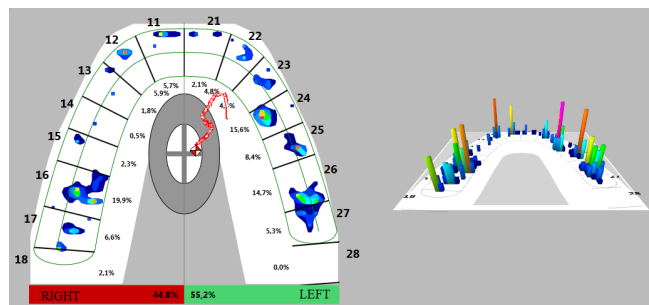


Figure 3.2. Dental caries of 36 tooth (antagonist)

Figure 3

to note that 16 and 17 opposite teeth equally distribute masticatory force. Premature occlusal contacts detected on 16 and 17 teeth, and dominated on the second molar (Fig. 4.2).

Analyzing the obtained previous data about influence of carious lesions of the teeth, one can make an assumption about the following. Carious lesion of the first molar leads to redistribution of occlusal contacts, namely the emphasis of occlusal force is transferred to the tooth with a large area of occlusal surface and the center of strength is located on the side of the jaw with affected tooth, which can be confirmed to some extent. The emphasis on occlusal stress is not tolerated on teeth with smaller occlusal surface, for example, on premolars. The same can be said about the antagonist pair of teeth. Received preliminary results give an opportunity to in-depth study of mechanisms and correlations between occlusal disorders and carious disease and complete the publications of authors on this subject which showed that teeth with carious process have formed the signs and symptoms of occlusal overload. However, currently there is no data regarding the specific features of the formation of occlusal disorders in background caries [2, 10, 20].

Changing of occlusal determinants play a dominant role (over 60%) in the development of occlusal disorders of maxillofacial part. As a result, we can see the changes of shape of occlusal surface, the displacement of cusps and fissures, which leads to loss of stability of tooth contact locations and further development of masticatory-chewing system [4, 5, 9, 11, 18].

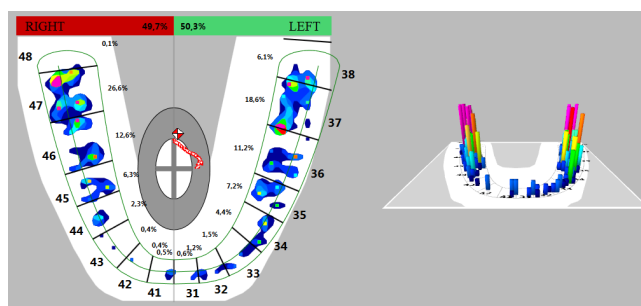


Figure 4.1. Dental caries of 46 tooth

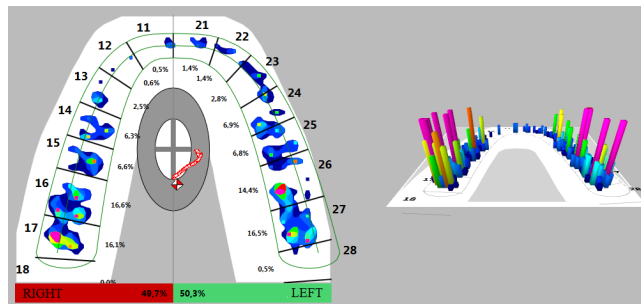


Figure 4.2. Dental caries of 46 tooth (antagonist)

Figure 4

3. Conclusions

Occlusal surfaces of the first molars are the most vulnerable places for the carious process. The method of determining the clinical forms of caries using diagenodent (Kavo) is the most objective. It functions with the help of laser fluorescence technology, which allows to detect caries in early stages and its prevalence in the tissues of the tooth.

Carious disease (caries) is one of the causes of formation of occlusal disorders. The computer system T-Scan Novus was used for their detection. This system allowed visualize on the screen images of all contacts, the sequences of occurrence, distribution of the forces on each and the location of the force center. The results of our research indicate that carious process has a direct effect on occurrence of occlusal disorders.

4. The prospect of further research

The prospect of further research is establishing of correlation between carious lesions and occlusal disorders and creation of treatment-and-prophylactic complex.

5. Conclusions

In conclusion, each PD center has to do a map of the most common causes of peritonitis, as well as their sensitivity to antibiotics. This is important due to the adaptation of therapeutic protocols for treatment of CAPD-related peritonitis for each center specifically. However, the rare causes of peritonitis should not be ignored, especially those which can lead

to increased morbidity and mortality in a certain group of patients.

References

- [1] Abolmasov NN. Yzbyratelnaia pryshlyfovka zubov. Smolensk; 2004. p. 8-9, 19-32.
- [2] Bragareva NV. Efektivnost obsledovaniya i lecheniya patsientov s razlichnymi faktorami kompensatsii okklyuzionnykh vzaimootnosheniy pri fiziologicheskoy okklyuzii [dissertatsiya]. Stavropol; 2014. 130 p.
- [3] Douson PE. Funktsionalnaya okklyuziya. Perevod s angliyskogo pod redaktsiyei Koneva DB. Moskva: Prakticheskaya meditsina; 2016. Chast 1, Funktsionalnaya harmoniya. Glava 1, Kontseptsiya polnotsennoy stomatologii; p. 15-22.
- [4] Zhehulovych ZIe. Kliniko-instrumentalniy analiz poslidovnosti formuvannya dentalnykh okliuziinykh kontaktiv pry zmykanni shchelep. Medychna nauka Ukrainy. 2015;11(1-2):69-74.
- [5] Zhehulovych ZIe. Klinichna kharakterystyka dentalnoi okliuzii pislia vidnovlennia u konformatyvnomu pidkhodi. Novyny stomatologii. 2015;2(83):18-23.
- [6] Zhehulovych ZIe. Ortopedychne likuvannya, prohnozuvannya ta profilaktyka okliuziinykh porushen zhuvalnogo aparatu [avtoreferat]. Kyiv: NMU im. Bohomoltsia. 2017. 20 p.
- [7] Zakharova HE. Zminy struktury okliuziinoi poverkhni zubnykh riadiv vnaslidok vtraty pershykh postiinykh moliariv. Suchasna stomatolohiia. 2007; 3(39):132-7.
- [8] Zakharova HE. Patohenez, profilaktyka ta likuvannya okliuziinykh porushen u osib z vtratoi pershykh postiinykh moliariv [avtoreferat]. Kyiv: NMU im. Bohomoltsia. 2009. 20 p.
- [9] Klineberg I, Dzhagera R redaktoryi. Perevod s angliyskogo pod redaktsiyei Antonika MM. Moskva: MEDpress-inform; 2006. 200 p.
- [10] Leshchuk LS. Vyznachennia dilianok sylovykh napruzhen v zubi pid chas funktsionalno-okliuziynoho navantazhennia. Sovremennaia stomatolohiia. 2013;1(65):122-5.
- [11] Mamedova LA. Pod hnetom okkliuzyy. Stomatoloh Ynfo. 2016;11/12: 22-4.
- [12] Nespriadko VP, Zhehulovych ZE, Zakharova HE. Narushenye okkliuzyonnykh vzaimootnosheniy pry povredzhenniy pervukh moliarov. Sovremennaia stomatolohiia. 2002; 4: 86-9.
- [13] Rozhko MM, redaktor. Stomatolohiia: pidruchnyk. Knyha 2. Kyiv. VSV "Medytsyna", 2013;p. 74-75.
- [14] Semenenko YuI., Semenenko IP., Yerys LB. Elektromiografichnyi kontrol reabilitatsii khvoroho z chastkovoio vtratoi zubiv, uskladnenoiu patolohichnym styranniam, vtorynnoi deformatsiieiu zubiv ta znyzhenym prykusom. Ukrainskyi stomatolohichnyi almanakh. 2013; 4: p. 93.
- [15] Sivovol SI. Okklyuziya zubov i zhevatel'naya effektivnost. Stomatolog Info. 2016; 11-12:12-13.
- [16] Carvalho JC. Caries Process on Occlusal Surfaces: Evolving Evidence and Understanding. Caries Res.2014;48(4):339-46. DOI: <https://doi.org/10.1159/000356307> [PMid:24577073]
- [17] Craddock HL. Occlusal Changes Following Posterior Tooth Loss in Adults. Part 3: A Study of Clinical Parameters Associated with the Presence of Occlusal Interferences Following Posterior Tooth Loss. J Prosthodont. 2008;2(18): 25-30.
- [18] Okeson JP. Management of Temporomandibular Disorders and Occlusion. 7th ed. St. Louis: Elsevier, Mosby, 2008. 1064 p
- [19] Roberson TM, Heymann HO, Swift EJ. Art and science of operative dentistry. 2012; p. 39-40
- [20] Wassell R, Naru A, Steel J. Applied Occlusion. London: Quintessence Publ. Co. LTd; 2008. 358 p.

Received: 2018-12-04

Revised: 2018-12-18

Accepted: 2018-12-20