

Neurogenic Myositis Ossificans of the Hip in a Patient with Axonal Polyneuropathy

Oubaddi Tlaite^{1*} , Imrani Kaoutar¹ , Rostoum Soufiane¹ , Moatassim Billah Nabil¹ , Nassar Ittimad¹

Abstract

Background. Neurogenic myositis ossificans is a rare entity defined by the development of soft tissue ossifications in patients with paraplegia or tetraplegia following neurological pathologies, often after cranial or spinal cord trauma. The diagnosis is based on imaging, in particular CT scan, which often reveals the presence of intramuscular ossifications of periarticular location. Treatment is based on analgesics, physiotherapy, and surgery as a last resort.

Case Report. We present a case of neurogenic myositis ossificans in a 26-year-old patient followed for axonal polyneuropathy secondary to vitamin deficiency.

Conclusions. Neurogenic myositis ossificans is a rare entity but is easily diagnosed, given the context of severe neurological disorders and the characteristic appearance on CT scan. In doubtful and atypical cases, a biopsy with histological study is recommended.

Keywords

Neurogenic Myositis Ossificans; Neurologic Disorders; CT Scan; Case Report

¹ Central radiology department, Ibn Sina University Hospital Center, Rabat, Morocco

*Corresponding author: toubaddi@gmail.com



Copyright ©Oubaddi Tlaite, Imrani Kaoutar, Rostoum Soufiane, Moatassim Billah Nabil, Nassar Ittimad, 2022

Introduction

Neurogenic myositis ossificans is a rare benign pseudotumor disorder characterized by intramuscular heterotopic ossifications in patients with severe neurological disorders. The clinical symptoms are nonspecific and usually include the appearance of a painful mass, hence the importance of imaging, in particular CT scan, which plays a crucial role in positive diagnosis and allows for a detailed analysis of the affected muscles, to make a detailed assessment for guiding possible surgery and eliminating the differential diagnoses. We report a rare case of neurogenic myositis ossificans occurring in a patient followed for axonal polyneuropathy secondary to vitamin deficiency.

Case Report

A 26-year-old woman with no history of trauma or a brain injury followed for a history of psychiatric disorders and several suicide attempts by ingestion of caustic agents; hypovitaminosis B₆, B₉, and B₁₂ complicated by axonal polyneuropathy with paraplegia, severe neurogenic atrophy of skeletal muscle. Vitamin deficiency was treated with oral vitamin B and folic acid supplement. After one year, the patient presented with bilateral inguinal pain lasting for two months. Physical examination revealed a decrease in body

mass index to 14 kg/m²; neurological examination revealed the absence of deep reflexes in the lower limbs, with bilateral inguinal masses, painful and indurated, more marked on the right side. Laboratory data revealed discrete inflammatory syndrome with a C-reactive protein of 24 mg/L and an elevated white blood cell count of 12 000/mm³. No X-rays were done. A computed tomography (CT) scan of the pelvis with contrast agent injection (Fig. 1) showed multiple intramuscular pericoxofemoral calcifications, with more extensive region on the right, the coxofemoral, sacroiliac joints, flaky and confluent, showing a pseudotumor appearance; however, a periosteal reaction or associated bone lesion was absent.

A conservative treatment with non-steroidal anti-inflammatory drugs in combination with physiotherapy sessions, including icing without massage or stretching, relieved inguinal pain.

Discussion

Neurogenic myositis ossificans is a rare benign pseudotumor disorder, characterized by heterotopic neo-osteogenesis in soft tissues secondary to prolonged immobilization during comas in patients with head and/or spinal cord trauma, Guillain-Barré syndrome, some neurological disorders of

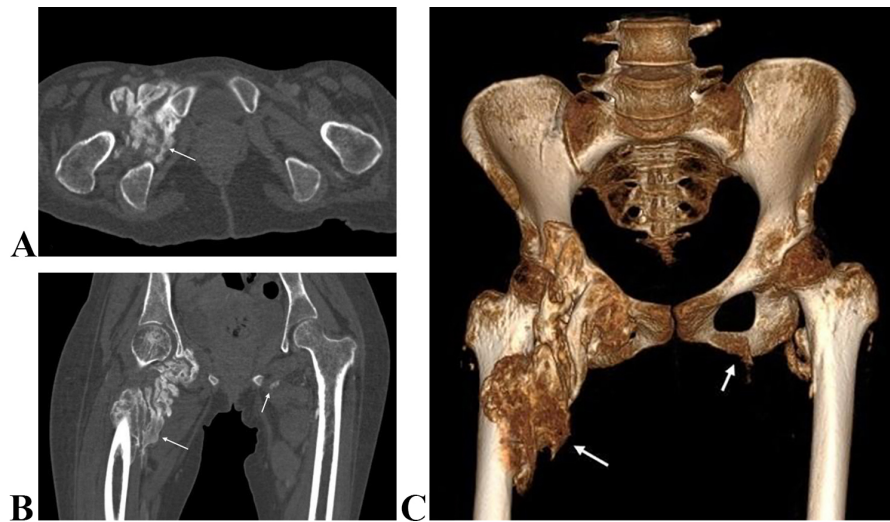


Figure 1. CT scan of the pelvis in axial section (A), coronal reconstruction (B), and volume rendering (C): multiple intramuscular calcifications of pericoxofemoral location, more marked on the right.

inflammatory, vascular, tumor-associated, or toxic origin [1, 2].

First described by Dejerine and Ceillier, neurogenic myositis ossificans occurring in patients with severe neurological disorders has been termed heterotopic ossification, para-articular ossification, hyperostosis, and myositis ossificans [3].

The incidence of neurogenic myositis ossificans after spinal cord injury is estimated to be 20-25% and following brain trauma – 10-23%. Other forms of acquired brain injury are accompanied by this condition less frequently [4].

The pathogenesis of neurogenic myositis ossificans is not well understood but seems to be related to an inflammatory phenomenon that stimulates mesenchymal stem cells to generate osteoblasts. Some authors suggest that prolonged immobilization leads to venous stasis in the paravertebral plexus, which stimulates neo-osteogenesis in the soft tissues [2]. Histologically, myositis ossificans is not distinguishable from the callus formation seen in normal bone healing [4].

The clinical symptoms include the appearance of a painful mass. Given the non-specific clinical and biological presentation, medical imaging remains the gold standard for positive diagnosis and follow-up [2].

The radiological aspect is characterized by the presence of a mass developed at the expense of a muscle or muscle group, containing centripetal dystrophic calcifications. CT scan is the reference examination for positive and differential diagnosis, as well as for preoperative assessment, thanks to multiplanar reconstructions, which allow for programming and guiding surgery.

Plain radiography can reveal calcifications as well. Ultrasound is of interest for early diagnosis of patients in intensive care, revealing hypertrophy with hyperemia and structural disorganization in muscle fibrils that precede calcifications.

Magnetic resonance imaging (MRI) plays a role in early diagnosis as well, by detecting periarticular inflammatory changes [1, 2]. On MRI, an iso or slight hyperintensity can

be noted inside the intramuscular mass on T1W and T2W images, respectively, with adjacent inflammatory edema. After injection of gadolinium, a peripheral enhancement corresponding to an active hypervascularized osteoid matrix can be observed [5].

Differential diagnoses for acute or subacute myositis ossificans include muscle abscess, sarcomas, focal myositis, and rhabdomyolysis. In case of large calcifications and contact with the bone cortex, the differential diagnosis is made between osteosarcoma, parosteal osteosarcoma, osteochondroma, and chronic avulsions, but myositis ossificans show characteristic peripheral calcifications, which are not seen in other calcifying soft tissue lesions. When the characteristic calcified appearance or clinical findings are not typical for neurogenic myositis ossificans, a biopsy may be necessary to confirm the diagnosis [6].

In mild cases, therapy is conservative based on non-steroidal anti-inflammatory drugs and physiotherapy. The use of physiotherapy to improve passive range of motion as a specific treatment for neurogenic heterotopic ossification had previously raised concerns about heterotopic bone microfractures leading to additional injury or even hematoma. The current consensus is that it provides an overall benefit in terms of maintaining joint range of motion [4]. Surgery is indicated for forms associated with neurological complications and for forms involving tendon insertion [2, 4].

Conclusions

Neurogenic myositis ossificans is a rare entity but is easily diagnosed, given the context of severe neurological disorders and the characteristic appearance on CT scan. In doubtful and atypical cases, a biopsy with histological study is recommended.

Ethical Statement

The research was conducted according to the Declaration of Helsinki.

Informed Consent

Written informed consent was obtained from the patient who participated in this case.

Data Availability

The data used to support the findings of this case are included within the article.

Conflict of Interest

The authors declared no conflicts of interest.

Financial Disclosure

This research received no specific grant from any funding agency in the public, commercial, or not-for-profit sectors.

References

- [1] Ezra J, Roffi F, Eichwald F, Le Breton C, Safa D, Mompont D, et al. Imagerie des complications neuro-orthopediques des traumatismes graves (rachis exclu). *Journal de Radiologie*. 2009;90(10):1275–1276. Available from: [https://doi.org/10.1016/S0221-0363\(09\)75088-7](https://doi.org/10.1016/S0221-0363(09)75088-7)
- [2] Alouini-Mekki R, El Mhabrech H, Hasni I, Allani M, Jemni H, Gamaoun W, et al. Myositis ossificans circumscripta: the contribution of imaging. *Journal de Radiologie*. 2007;88(5):663–668. Available from: [https://doi.org/10.1016/S0221-0363\(07\)89873-8](https://doi.org/10.1016/S0221-0363(07)89873-8)
- [3] Carlier RY, Safa DML, Parva P, Mompont D, Judet T, Denormandie P, et al. Ankylosing neurogenic myositis ossificans of the hip. *The Journal of Bone and Joint Surgery British volume*. 2005;87-B(3):301–305. Available from: <https://doi.org/10.1302/0301-620X.87B3.14737>
- [4] McCormack R, McGlone B. Neurogenic heterotopic ossification: a pictorial review. *British Journal of Hospital Medicine*. 2019;80(12):707–710. Available from: <https://doi.org/10.12968/hmed.2019.80.12.707>
- [5] Lacout A, Jarraya M, Marcy P-Y, Thariat J, Carlier RY. Myositis ossificans imaging: keys to successful diagnosis. *Indian Journal of Radiology and Imaging*. 2012;22(01):35–39. Available from: <https://doi.org/10.4103/0971-3026.95402>
- [6] Tyler P, Saifuddin A. The imaging of myositis ossificans. *Seminars in Musculoskeletal Radiology*. 2010;14(02):201–216. Available from: <https://doi.org/10.1055/s-0030-1253161>

Received: 2022-09-15

Revision Requested: 2022-10-09

Revision Received: 2022-10-14

Accepted: 2022-10-15